

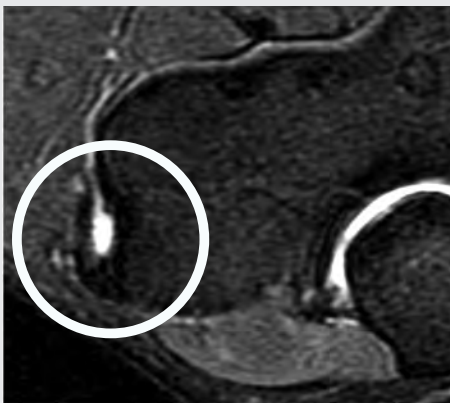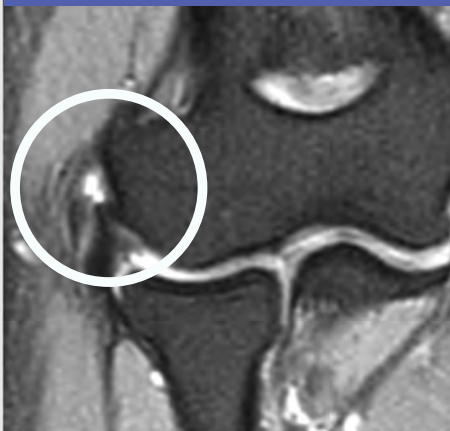Case Study: Common Extensor Tendon Tear

+ PATIENT: 34 year-old male, 1 year of pain
MRI: Common extensor tendon tear

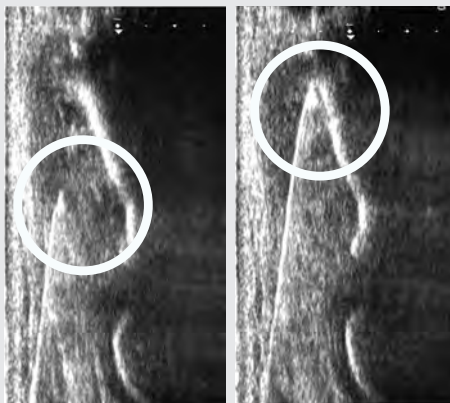
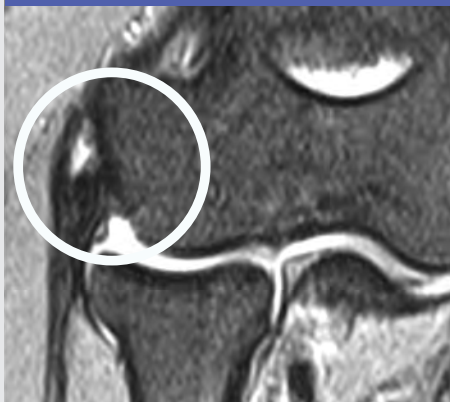RECALCITRANT TO: Failed conservative treatment; PT, anti-inflammatory meds, vicodin
PRIOR TREATMENT: 1 steroid injection with increased pain

AMNIOFIX® TREATMENT: AmnioFix® Injectable (40 mg) (2) ultrasound guided injections month 8 and 11
RESULTS: 80% reduction of symptoms after 1 treatment; complete resolution after 2nd treatment

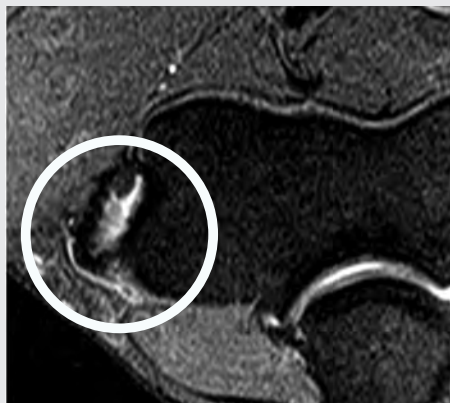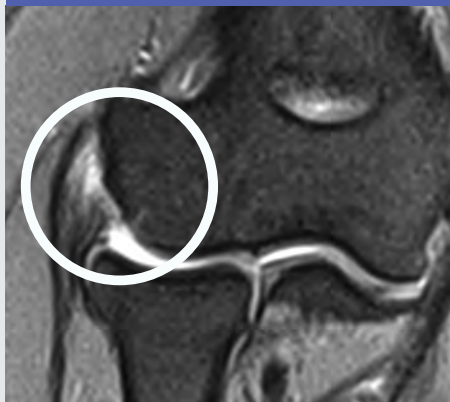MONTH 1 INITIAL PRESENTATION



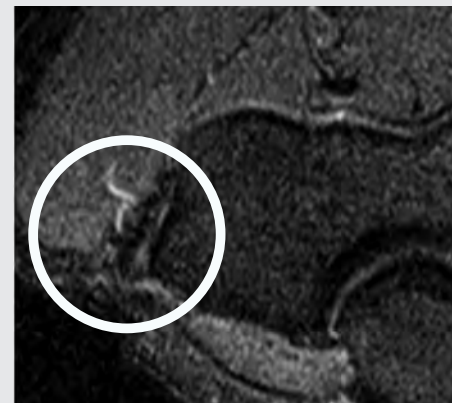
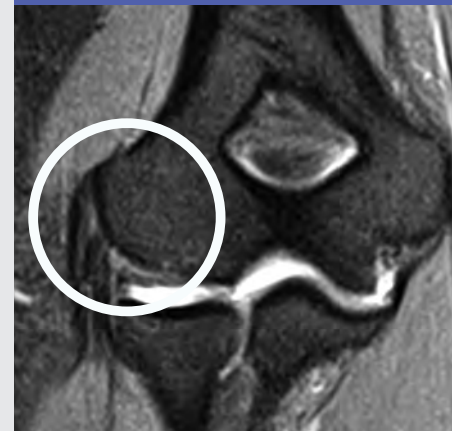MONTH 7 FIRST ULTRASOUND GUIDED AMNIOFIX® INJECTABLE INJECTION



MONTH 11 POST AMNIOFIX® INJECTION, SECOND AMNIOFIX® INJECTABLE INJECTION



MONTH 15 POST AMNIOFIX® INJECTION



Photos Courtesy of Rahul Desai, MD; RestorePDX Sports & Spine, Portland, OR